

Combination of Intraspine Interlaminar Device With Lumbar Discectomy in Patients With L5/S1 Disc Herniation

Shitong Feng

Department of Orthopaedics, Beijing Friendship Hospital, Capital Medical University

Zihan Fan

Department of Orthopaedics, Beijing Friendship Hospital, Capital Medical University

Xiang Li

Department of Orthopaedics, Beijing Friendship Hospital, Capital Medical University

Jisheng Lin

Department of Orthopaedics, Beijing Friendship Hospital, Capital Medical University

Yong Yang

Department of Orthopaedics, Beijing Friendship Hospital, Capital Medical University

Qi Fei (✉ spinefei@126.com)

Department of Orthopaedics, Beijing Friendship Hospital, Capital Medical University, 100050, China.

Research article

Keywords: Lumbar Disc Herniation, L5/S1, IntraSpine, Non-fusion Technique, Interlaminar, Dynamic Stabilization Devices

DOI: <https://doi.org/10.21203/rs.3.rs-64740/v1>

License: © ⓘ This work is licensed under a Creative Commons Attribution 4.0 International License.

[Read Full License](#)

Abstract

Background. It is commonly recognized that interspinous spacers were not generally suitable for the application in L5-S1 level due to the short S1 spinous process. In this retrospective study, the feasibility and validity of the IntraSpine interlaminar device in the treatment of lumbar disc herniation on the L5/S1 level were evaluated.

Methods. During the January 2018 and December 2018, a total of 30 patients, who were hospitalized in our hospital due to lumbar disc herniation (LDH) on the L5/S1 level, were included in the current study. The clinical symptoms before surgery, post-operation (3 days after surgery), 6 months after surgery, 12 months after surgery, and final follow-up were assessed using the back and leg visual analog scale (VAS), Oswestry disability index (ODI). Sagittal diameter of the lumbar spinal canal (SD), posterior disc height (PDH), left and right foramina height (LFH and RFH), left and right foramina width (LFW and RFW) were measured by sagittal reconstructions of CT scans. The range of motion (ROM) of L5-S1 level was estimated by lumbar dynamic X-ray images.

Results. The back VAS, leg VAS, ODI, were significantly improved after surgery ($P < 0.05$). The SD, PHD, LFH, RFH, LFW, and RFW after the operation and in the follow-up period were statistically different from those before surgery ($P < 0.05$). The ROM of L5/S1 level at final follow-up was not statistically different from that before surgery ($P = 0.299$). 93.3% of patients demonstrated successful outcomes.

Conclusions. The combination of IntraSpine interlaminar device with lumbar discectomy is an effective minimally invasive procedure for the treatment of L5/S1 disc herniation, which can delay and prevent the reduction of the disc height after discectomy in L5/S1 segment.

Introduction

Low back pain due to lumbar disc herniation has become a significant public health problem. The related report pointed out that 2.75 out of 1000 people with episodes of low back pain will suffer an event of hospitalization.¹ Lumbar fusion surgery as the classical method has been an efficient method for the treatment of various lumbar degenerative diseases and provides satisfactory results in a high proportion of patients.² However, fusion is not always perfect to some extent since the stabilization of the affected segment may lead to the loss of mobility as a functional spinal unit and acceleration of adjacent segment degeneration.³ Simple open lumbar discectomy (OLD) and transforaminal percutaneous endoscopic lumbar discectomy (PELD) was the other effective surgical procedures for lumbar disc herniation (LDH).⁴ However, early literature have reported the increase in instability after simple OLD resulted in recurrence of spinal canal stenosis and deterioration of operative results⁵⁻⁷. Besides, surgeons have started to pay an increasing number of attentions to the recurrence and a long recovery process after transforaminal PELD in recent years^{8,9}. Literatures revealed the recurrence rate of transforaminal PELD was 0–7.4%, and patients with central herniation were more likely to experience recurrent herniation

compared with patients with paramedian herniation.¹⁰ Besides, the reduction of the disc height after operation is the non-ignorable long-term complications of PELD.¹¹

To overcome the weakness of traditional fusion technique, interspinous process devices (ISD), such as X-STOP, Wallis, and Coflex, were developed and presented more than ten years.¹²⁻¹⁴ However, in previous studies, owing to the unique characteristic of S1 spinous process—too small in size and weak in strength, implanting ISP in L5/S1 segment was regarded as a contraindication for its risks of fixation failure and shifting¹⁵⁻¹⁸.

Different from ISD, IntraSpine interlaminar device is the new interlaminar dynamic stabilization devices which were designed by Giancarlo Guizzardi and first used in clinical in 2007¹⁹. The core material of IntraSpine is flexible medical silica gel, and the surface material is polyester fiber, which can enlarge foramina, relief the pressure on facets and discs and stabilized spine without sacrifice its natural motion. The compression ratio of anterior and posterior part of IntraSpine interlaminar device are different. The mechanism of enlarge laminar space is mainly applied by anterior part of IntraSpine interlaminar device, which is closer to the ligamentum flavum. The posterior part of IntraSpine mainly apply the effect of dynamic stability, which is located in interspinous (Fig. 1). Furthermore, IntraSpine interlaminar device was closer to the axis of instantaneous rotation center of the spinal motion segment and was able to restrain the segmental instability, maintain the sagittal balance, and restore the physiologic movement of spinal motion segment.²⁰ In the designer's preliminary report, the application of IntraSpine interlaminar device in L5/S1 segment was feasible.²¹ But the preliminary study only reported the clinical data, including visual analog scale (VAS) and Oswestry disability index (ODI), the radiographic data were not mentioned. To the best of our knowledge, no study about the application of the IntraSpine interlaminar device at the L5/S1 level with lumbar discectomy.

This study aimed to evaluate the feasibility and validity of the IntraSpine interlaminar device in the treatment of lumbar disc herniation at L5/S1 level with lumbar discectomy by clinical and radiographic data.

Materials And Methods

During the January 2018 and December 2018, we retrospectively reviewed a consecutive series of 62 patients (74 levels) who were hospitalized in our hospital due to lumbar degenerative disease. All patients underwent IntraSpine (Cousin Biotech, France) implantation. 32 patients were excluded from this study due to multi-segment lumbar degenerative disease, without decompression, and IntraSpine interlaminar devices were implanted in other levels rather than L5/S1 segment. A total of 30 patients were enrolled in this study, whose degenerative lumbar segments were located at the L5-S1 level. They all underwent IntraSpine (Cousin Biotech, France) implantation with lumbar discectomy in the L5-S1 level. The inclusion and exclusion criteria were showed in Table 1.

Table 1
Inclusion and exclusion criteria

Inclusion criteria	Exclusion criteria
1) 18–65 years old.	1) Two or more segments were involved.
2) Conservative therapy was ineffective for at least 3 months.	2) Severe osteoporosis.
3) Confirmed lumbar disc herniation of single level at L5–S1 by MRI, with unilateral radicular pain.	3) II°–IV° Lumbar Spondylolisthesis in L5-S1 level.
4) L5-S1 level was confirmed as the responsible segment.	4) L5-S1 spinal stenosis was caused by osteophyte.
5) Image materials including X-ray, CT, MRI were available.	5) Severe intervertebral disc and small joint degeneration.
	6) Severe L5/S1 disc space narrowing (the disc height < 4 mm in CT scan).
	7) Surgical contraindications such as abnormal bleeding and coagulation function, severe organ diseases and so on.

Surgical procedure

All the procedures were completed by the same group of experienced surgeons to minimize the deviation. Patients who underwent general anesthesia were placed in the prone position. After sterile surgical preparation, a midline skin incision was made on the L5/S1 level. Periosteal muscle was dissected to expose the interspinous space and lamina. The lower two thirds of the interspinous ligament was resected, while the supraspinous ligament, spinous process, lamina, facet joint, and ligament flavum were retained. Unilateral neural decompression by fenestration through partial laminectomy was performed. During the process of the partial laminectomy, the key steps were to resect ligamentum flavum and nucleus pulposus rather than destruct the lamina and facet joint. The lamina and facet joint should be destructed as little as possible to maintain the posterior column integrity of the lumbar spine. The base of the spinous process should be cleaned before placing IntraSpine interlaminar device. After the interlaminar space was expanded with dilation, the trial implant was tested to decide the most suitable size for implanting. After insertion of the implant, large pituitary forceps hold the implant to push and pull, to confirm its secure placement. The surgery ended after satisfactory implantation was confirmed by fluoroscopy. Then the surgical wound is closed in layers after irrigation.

Clinical data

The clinical data were evaluated by VAS of low back pain and leg pain and the ODI. Preoperative data and postoperative data (3 days after surgery) were collected by medical records. Follow-up data were completed by medical appointments or phone calls following-up (6 months, 12 months and the final follow-up). A decrease of at least 50% in the back and leg VAS and ODI at the last follow-up was regarded as successful outcomes.

Imaging data

Sagittal diameter of the lumbar spinal canal (SD), posterior disc height (PDH), left and right foramina height (LFH and RFH), left and right foramina width (LFW and RFW) were measured by sagittal reconstructions of CT scans. The range of motion (ROM) of the L5-S1 level was evaluated by the dynamic X-ray pictures. The demonstration of imaging measurement was shown in Fig. 2.

Statistical analysis

The paired-samples t-test was used to compare and evaluate the ODI, VAS, and radiographic data in subjects at different visiting time points. The non-normal data were analyzed using the non-parametric test. P-value ≤ 0.05 was considered statistically significant. Data were expressed as the mean \pm standard deviation (\pm SD), and the error bars in the figures refer to 95% confidence intervals. SPSS 21.0 (SPSS Inc., Chicago, IL, USA) software was used for statistical analysis.

Results

Thirty patients with a mean age of 39.3 ± 10.5 years (range, 23–65 years) were enrolled in the study, including 14 men and 16 women. According to preoperative Image materials, clinical symptoms, and signs, the L5-S1 level was definitely diagnosed as the responsible segment. All patients were scheduled to return for follow-up examinations and completed a minimum 12-month follow-up (23.2 ± 6.0 months, ranging from 12 to 35 months).

The average blood loss was 61.7 ± 32.1 ml, the average operation time was 62.8 ± 9.7 minutes, the average incision length was 5.1 ± 1.3 cm, and the average postoperative drainage was 20.6 ± 18.9 ml. The size of devices was 8 mm in 3 levels (10%), 10 mm in 12 levels (40%), 12 mm in 10 levels (33.3%), 14 mm in 5 levels (16.7%). (Table 2)

Table 2
Baseline of demographics and surgical information

Variables	Results
Demographics	30
Ages (years)	39.3 ± 10.5
Male	14 (46.7%)
Female	16 (53.3%)
Follow up duration (months)	23.2 ± 6.0
Bleeding (ml)	61.7 ± 32.1
Operative time (minutes)	62.8 ± 9.7
Incision length (cm)	5.1 ± 1.3
Postoperative drainage (ml)	20.6 ± 18.9
Implantation size	
8 mm	3 (10%)
10 mm	12 (40%)
12 mm	10 (33.3%)
14 mm	5 (16.7%)

Clinical symptoms

The non-parametric test showed that there were significant differences in ODI, back VAS, and leg VAS over time. The above indices at the post-operation, 6-month follow-up, 12-month follow-up, and final follow-up were significantly different from those before surgery ($P < 0.05$). (Table 3) Besides, the above indices at the 6-month follow-up, 12-month follow-up and final follow-up were significantly different from those after surgery ($P < 0.05$). (Table 4, Fig. 3) There were two patients whose leg VAS, back VAS, and ODI were less than 50%. 93.3% of patients achieved a successful outcome.

Table 3
Comparison of clinical and radiological parameters (mean ± SD).

Parameters	Preop	Postop	6 mon postop	12 mon postop	Final follow-up
ODI	34.9 ± 3.1	20.4 ± 4.4 ※	16.8 ± 5.6 ※	13.9 ± 6.1 ※	12.11 ± 6.1 ※
Back VAS	5.4 ± 0.9	3.7 ± 1.2 ※	2.7 ± 1.1 ※	2.5 ± 1.2 ※	2.2 ± 0.9 ※
Leg VAS	6.7 ± 1.1	3.4 ± 1.1 ※	2.5 ± 1.1 ※	2.2 ± 0.8 ※	2.2 ± 0.8 ※
SD, mm	11.2 ± 2.4	14.9 ± 2.6 ※	14.5 ± 2.5 ※	14.4 ± 2.6 ※	14.4 ± 2.7 ※
PHD, mm	5.7 ± 1.7	7.1 ± 1.7 ※	6.9 ± 1.8 ※	6.9 ± 1.7 ※	6.8 ± 1.7 ※
LFH, mm	15.8 ± 2.7	17.9 ± 2.9 ※	17.8 ± 3.0 ※	17.7 ± 3.0 ※	17.5 ± 3.0 ※
RFH, mm	15.6 ± 2.3	17.5 ± 2.7 ※	17.1 ± 2.5 ※	17.0 ± 2.5 ※	16.9 ± 2.5 ※
LFW, mm	5.3 ± 1.6	6.3 ± 1.2 ※	6.5 ± 1.3 ※	6.4 ± 1.4 ※	6.3 ± 1.4 ※
RFW, mm	5.6 ± 1.7	6.7 ± 1.3 ※	6.8 ± 1.2 ※	6.8 ± 1.2 ※	6.6 ± 1.1 ※
ROM, degree	5.2 ± 4.0				4.4 ± 3.4 †
※ Versus preoperative, P < 0.05. † Versus preoperative, P > 0.05.					
<i>ODI</i> Oswestry Disability Index, <i>VAS</i> Visual Analog Scale, <i>SD</i> sagittal diameter of lumbar spinal canal, <i>PHD</i> posterior disc height, <i>LFH</i> left foramina height, <i>RFH</i> right foramina height, <i>LFW</i> left foramina width, <i>RFW</i> right foramina width.					
<i>ODI</i> Oswestry Disability Index, <i>VAS</i> Visual Analog Scale, <i>SD</i> sagittal diameter of lumbar spinal canal, <i>PHD</i> posterior disc height, <i>LFH</i> left foramina height, <i>RFH</i> right foramina height, <i>LFW</i> left foramina width, <i>RFW</i> right foramina width, <i>ROM</i> range of motion of L5-S1 level.					

Table 4
Comparison of clinical and radiological parameters (mean ± SD).

Parameters	Postop	6 mon postop	12 mon postop	Final follow-up
ODI	20.4 ± 4.4	16.8 ± 5.6 ※	13.9 ± 6.1 ※	12.11 ± 6.1 ※
Back VAS	3.7 ± 1.2	2.7 ± 1.1 ※	2.5 ± 1.2 ※	2.2 ± 0.9 ※
Leg VAS	3.4 ± 1.1	2.5 ± 1.1 ※	2.2 ± 0.8 ※	2.2 ± 0.8 ※
SD, mm	14.9 ± 2.6	14.5 ± 2.5 †	14.4 ± 2.6 †	14.4 ± 2.7 ※
PHD, mm	7.1 ± 1.7	6.9 ± 1.8 †	6.9 ± 1.7 †	6.8 ± 1.7 ※
LFH, mm	17.9 ± 2.9	17.8 ± 3.0 †	17.7 ± 3.0 †	17.5 ± 3.0 †
RFH, mm	17.5 ± 2.7	17.1 ± 2.5 †	17.0 ± 2.5 †	16.9 ± 2.5 ※
LFW, mm	6.3 ± 1.2	6.5 ± 1.3 †	6.4 ± 1.4 †	6.3 ± 1.4 †
RFW, mm	6.7 ± 1.3	6.8 ± 1.2 †	6.8 ± 1.2 †	6.6 ± 1.1 †
※ Versus postoperative, P < 0.05. † Versus postoperative, P > 0.05.				
<i>ODI</i> Oswestry Disability Index, <i>VAS</i> Visual Analog Scale, <i>SD</i> sagittal diameter of lumbar spinal canal, <i>PHD</i> posterior disc height, <i>LFH</i> left foramina height, <i>RFH</i> right foramina height, <i>LFW</i> left foramina width, <i>RFW</i> right foramina width.				

Imaging results

The X-rays showed that ROM of L5/S1 level at final follow-up was not statistically different from that before surgery ($P = 0.299$). (Table 3)

CT images indicated that the SD, PHD, LFH, RFH, LFW, and RFW after operation were statistically different from those before surgery ($P < 0.05$). The above indices at the 6-month follow-up, 12-month follow-up and final follow-up were significantly different from those before the operation ($P < 0.05$). (Table 3) The above indices at the 6-month follow-up and 12-month follow-up were not statistically different from those after the operation ($P > 0.05$). However, imaging data of SD, PHD and RFH decreased at final follow-up when compared with postoperative data ($P < 0.05$). While the data of LFH, LFW, RFW at final follow-up decreased without significantly difference when compared with postoperative data ($P > 0.05$). (Fig. 4, Table 4)

All patients were able to do the ground exercise the second day after surgery with the help of brace-wear under the doctor's supervision. No one had an infection and a secondary operation. One case was found the position of the IntraSpine interlaminar device shifting to the edge of the S1 spinous process during the follow-up period. But this patient did not suffer from relative symptoms. Meanwhile, we noticed that the device shifting in follow-up imaging data weren't aggravated significantly compared with

postoperative data. After obtaining the patient's informed consent, we decided to keep continuing observation for this patient. The patient was still asymptomatic until the last phone call following-up.

Discussion

Animal models revealed that the intradiscal pressure might be reduced when continuous axial pressure was applied to the spinal column, resulting in degeneration of the intervertebral disc, while traction of the spine could stabilize the intradiscal pressure and reverse or prevent disc degeneration to some extent²². According to above theory, conservative traction therapy has been applied to alleviate the clinical symptoms of LDH²³. However, the spine is under compressive loads due to patient body weight, which may result in reducing the effect of traction therapy when the patients are standing. The retraction effect of ISD or interlaminar device is similar to that of conservative traction therapy, which can maintain the sustained effect on the spine by the time the patients are standing. That is, ISD or interlaminar device converts conservative in vitro traction therapy into sustained in vivo traction²⁴.

Open lumbar discectomy (OLD) is the early technique for LDH with reduced disc height, segmental instability and retrolisthesis, which may be a source of postsurgical pain²⁵. Percutaneous endoscopic lumbar discectomy (PELD) is a minimal invasive spinal technique for LDH, which has gained popularity and shown successful results. PELD has many advantages such as less paraspinal muscle trauma, preserving facet joint, which minimize postoperative instability to some extent²⁶. However, both OLD and PELD are the direct intervention of discectomy, which causes a decrease of the disc space inevitably.¹¹ Extended removal of a disc and the consecutive reduction of the disc height may lead to spinal instability and chronic facet joint pain²⁷. To prevent the reduction of the disc height after discectomy is necessary for the treatment of LDH.

The dynamic stabilization device as an alternative to fusion technique in the treatment of lumbar degenerative diseases has been widely applied. In related literature, Dr. Knowles was recognized as the pioneer of interspinous process devices in the 1950s²⁸. Interspinous spacers were typical representative of the dynamic stabilization devices. However, the related complications, including the intraoperative spinous process fractures, spinous process fatigue fracture, supra-spinous ligament ruptured were gradually reported in recent years.^{16,17} Even if Xu et al. made attempts to apply Coflex(a "U"-shaped titanium alloy spacer) in L5-S1 lumbar degenerative diseases, he had to admit that the prosthesis was prone to shifting and couldn't offer enough supporting strength by a conventional method due to the short S1 spinous process²⁹. What's more, the device-related complications of Coflex caused by excessive load on spinous process and the patient's degree of osteoporosis, including spinal process fracture, device loosening, and fixed-wing breakage, were not unusual in literatures^{30,31}. Thereby, it is commonly recognized that interspinous spacers were not generally suitable for the application in L5-S1 level.^{15,18}

IntraSpine as a new interlaminar dynamic stabilization device for application in lumbar degenerative diseases is closer to the lamina and deeper than ISD when implanted. Interlaminar spacer could

compensate the physiological load on lumbar spine from the facet joints, provides direct neurological decompression, and reestablishes the foraminal height³². Our hospital developed this technique since August 2017. The designer initially assumed that the indications were low back pain caused by disc degeneration, lumbar instability, young patients after lumbar discectomy, chronic low back pain caused by the syndrome of zygapophyseal joints, etc³³. The related clinical reports about the application of IntraSpine interlaminar device are rare at present, and the indications need verifying and probing.

In our study, IntraSpine interlaminar device could be regarded as the easily applied and minimally invasive technique for less operative time, blood loss, and postoperative volume of wound drainage, which was conformed with previous study¹⁹. The previous study indicated that the IntraSpine could significantly improve functional status in patients with chronic low back pain³⁴ and relieve the chronic low back pain due to Baastrup disease³⁵. In the current study, patients' back and leg VAS, ODI had significant improvement after the operation. The physical pain was relieved, lower limb function and quality of life were improved, with 93.3% of patients achieving a successful outcome. Hence, the improvement of symptoms was similar to the above studies.

In Carrabs's small sample, ten IntraSpine interlaminar devices were implanted in 10 single-level procedures with a 6-month follow-up period. In their report, the radiological results revealed that IntraSpine interlaminar device was able to reduce the workload on adjacent levels compared with interspinous spacers³⁶. Furthermore, the percentage composition of cortical bone in lamina is higher than spinal process, which admits lower influence of osteoporosis. Therefore, we consider that the above feature is the advantage for the use of IntraSpine interlaminar device. In our study, the post-operative SD, PDH, LFH, RFH, LFW, and RFW increased by 33.0%, 24.6%, 13.3%, 12.2%, 18.9%, 19.6% when compared with pre-operative data. That is, IntraSpine was verified to significantly enlarge the spinal canal and neuro foramen by distracting the intervertebral space, reducing the workload of the intervertebral disc and facet joint. Meanwhile, there was no significant difference between follow-up ROM and pre-operative ROM, indicating that IntraSpine interlaminar devices can maintain the physiologic movement of the spinal motion segment.

It's important to note that the improvement of symptoms mainly because of the lumbar discectomy. The function of IntraSpine interlaminar device is to enlarge the sagittal diameter of the lumbar spinal canal, expand the foramina, increase the posterior disc height, and then prevent the reduction of the disc height after discectomy, playing a positive role in alleviating the symptoms.

What's more, Imaging data of SD, PHD and RFH decreased at final follow-up by 3.4%, 4.2%, 3.4%, when compared with postoperative data ($P < 0.05$). While the data of LFH, LFW, RFW at final follow-up decreased without significantly difference when compared with postoperative data ($P > 0.05$). This statistical phenomenon may be caused by the small sample size in our study. A retrospective study revealed that patients with X-STOP had the most significant improvements in FH, FW, and FA; however, PDH, FH, and FA during follow-up were decreased by 17.9%, 5.6%, and 11.4%, respectively, compared with those immediately after surgery³⁷. Another two studies found similar results^{15,38}. That is, the slight

decrease of PHD is ubiquitous during follow-up when compared with those immediately after operation. However, though there was a loss in SD, PHD and RFH in this study, the values of IntraSpine were still better than those in previous studies on ISD devices. In terms of IntraSpine, the decrease of imaging data was understandable due to the material of IntraSpine interlaminar device. We speculate that flexible medical silica gel as the primary material, which occurred slight deformation due to pressure imposed on the prosthesis. But the decreases in imaging data were slight and acceptable, which didn't mean a significant and continuous decline.

In our follow-up period, we found that the position of the IntraSpine interlaminar device shifted to the edge of the S1 spinous process in one case. During the operation of this patient, we found that 10 mm-size of the device seemed to be a little smaller while the 12 mm-size was larger when measuring the spacing. 10 mm-size of the device was chosen finally, and we speculated that the mismatching selection might be the risk actor of device shifting. Hence, we tended to choose the larger size of devices in our subsequent cases while encountering similar situation. There was no recurrence of devices shifting subsequently. Moreover, the the less resection of lamina in laminectomy might prevent the device from invading into the spinal canal. The reservation of supraspinous ligament might limit the device from shifting continuously even falling out.

Furthermore, we noticed that position of the IntraSpine interlaminar device rearward shifting slightly in initial series of cases. But these patients did not complaint relative discomforts such as significant back and leg pain. Besides, the patients' clinical symptoms were still satisfactorily relieved without recurrence. We presume that the small size of the S1 spinous process leads to slightly rearward shifting of the device. In addition, we just implanted the device into the intralaminar without any other additional fixation in initial cases. Therefore, we firmly fixed four corners of the IntraSpine to supraspinous ligament by 10# silk thread after inserting device. Few shifting of the device recurred in subsequent cases after we modified the procedure.

In our study, we noticed that the IntraSpine interlaminar device couldn't be clearly observed by X-ray at the L5-S1 level due to the unique structure. Therefore, both CT and X-ray were indispensable in the clinical follow-up period.

Limitations

There are several limitations to this study. First, our study design is a retrospective, self-contrasted study without randomization. Second, due to the small sample size of this study, further investigation should be performed on a larger scale to reduce the risk of bias. Third, because a few of medical institutions develop the technique of IntraSpine interlaminar device, multicenter prospective studies can't be achieved at present. Besides, more extended postoperative follow-up periods are necessary to evaluate the long-term clinical efficacy in our subsequent study.

Conclusion

The combination of IntraSpine interlaminar device with lumbar discectomy is the feasible procedure for the treatment of the lumbar disc herniation in L5-S1 level, which can significantly alleviate the symptoms and improve patient quality of life. Imaging revealed that it can enlarge the sagittal diameter of the lumbar spinal canal, expand the foramina, increase the posterior disc height, and maintain the normal sagittal ROM of the L5-S1 segment. This combination can effectively delay and prevent the reduction of the disc height after discectomy in L5/S1 segment.

List Of Abbreviations

VAS

visual analog scale; ODI:Oswestry disability index; SD:sagittal diameter of the lumbar spinal canal; PDH:posterior disc height; LFH:left foramina height; RFH:right foramina height; LFW:left foramina width; RFW:right foramina width; ROM:range of motion (ROM); LDH:lumbar disc herniation; OLD:open lumbar discectomy; PELD:percutaneous endoscopic lumbar discectomy; ISD:interspinous process devices.

Declarations

Ethical approval and consent to participate

This study is only involving objective retrospective description, so it is not applicable to ethics approval and the patient has given her consent for the use of physical and imaging information adopted from the patient.

Consent for publication

No conflict of interest exists in the submission of this manuscript, and manuscript is approved by all authors for publication

Availability of data and materials

The datasets generated and analyzed during the current study are not publicly available due to the need of subsequent study, but are available from the corresponding author on reasonable request.

Competing interests

The authors declare that they have no conflict of interest.

Funding

This research did not receive any specific grant from funding agencies in the public, commercial, or not-for-profit sectors.

Authors' contributions

Qi Fei and Yong Yang was responsible for conception and design of the study. Shitong Feng and Zihan Fan prepared and completed the manuscript. Xiang Li and Jisheng Lin analyzed the data. All named authors wrote this manuscript and have agreed to the publication of this manuscript, and it does not infringe on any copyright or property rights.

Acknowledgements

All authors disclose any financial and personal relationships with other people or organizations that could inappropriately influence their work.

References

1. Heliovaara M, Knekt P, Aromaa A. Incidence and risk factors of herniated lumbar intervertebral disc or sciatica leading to hospitalization. *J Chronic Dis*. 1987;4:251–8.
2. Cloward RB. The treatment of ruptured lumbar intervertebral discs by vertebral body fusion. I. Indications, operative technique, after care. *J Neurosurg*. 1953;10:154–68.
3. Yang Y, Hong Y, Liu H, Song Y, Li T, Liu L, Gong Q. Comparison of clinical and radiographic results between isobar posterior dynamic stabilization and posterior lumbar inter-body fusion for lumbar degenerative disease: A four-year retrospective study. *Clin Neurol Neurosurg*. 2015;136:100–6.
4. Fan G, Han R, Gu X, Zhang H, Guan X, Fan Y, Wang T, He S. Navigation improves the learning curve of transforaminal percutaneous endoscopic lumbar discectomy. *Int Orthop*. 2017;41:323–32.
5. Yone K, Sakou T, Kawauchi Y, Yamaguchi M, Yanase M. Indication of fusion for lumbar spinal stenosis in elderly patients and its significance. *Spine (Phila Pa 1976)*. 1996;21:242–8.
6. Epstein NE, Epstein JA, Carras R, Lavine LS. Degenerative spondylolisthesis with an intact neural arch: a review of 60 cases with an analysis of clinical findings and the development of surgical management. *Neurosurgery*. 1983;13:555–61.
7. Lombardi JS, Wiltse LL, Reynolds J, Widell EH, Spencer C. 3rd. Treatment of degenerative spondylolisthesis. *Spine (Phila Pa 1976)*. 1985;10:821–7.
8. Burneikiene S, Nelson EL, Mason A, Rajpal S, Serxner B, Villavicencio AT. Complications in patients undergoing combined transforaminal lumbar interbody fusion and posterior instrumentation with deformity correction for degenerative scoliosis and spinal stenosis. *Surg Neurol Int*. 2012;3:25.
9. Villavicencio AT, Burneikiene S, Bulsara KR, Thramann JJ. Perioperative complications in transforaminal lumbar interbody fusion versus anterior-posterior reconstruction for lumbar disc degeneration and instability. *J Spinal Disord Tech*. 2006;19:92–7.
10. Yao Y, Liu H, Zhang H, et al. Risk Factors for Recurrent Herniation After Percutaneous Endoscopic Lumbar Discectomy. *World Neurosurg*. 2017;100:1–6.
11. Choi KC, Kim JS, Lee DC, Park CK. Percutaneous endoscopic lumbar discectomy: minimally invasive technique for multiple episodes of lumbar disc herniation. *BMC Musculoskelet Disord*. 2017;18:329.

12. Christie SD, Song JK, Fessler RG. Dynamic interspinous process technology. *Spine (Phila Pa 1976)*. 2005;30:73–8.
13. Kabir SM, Gupta SR, Casey AT. Lumbar interspinous spacers: a systematic review of clinical and biomechanical evidence. *Spine (Phila Pa 1976)*. 2010;35:E1499–506.
14. Holinka J, Krepler P, Matzner M, Grohs JG. Stabilising effect of dynamic interspinous spacers in degenerative low-grade lumbar instability. *Int Orthop*. 2011;35:395–400.
15. Park SC, Yoon SH, Hong YP, Kim KJ, Chung SK, Kim HJ. Minimum 2-year follow-up result of degenerative spinal stenosis treated with interspinous u (coflex). *J Korean Neurosurg Soc*. 2009;46:292–9.
16. Puzzilli F, Gazzeri R, Galarza M, Neroni M, Panagiotopoulos K, Bolognini A, Callovini G, Agrillo U, Alfieri A. Interspinous spacer decompression (X-STOP) for lumbar spinal stenosis and degenerative disk disease: a multicenter study with a minimum 3-year follow-up. *Clin Neurol Neurosurg*. 2014;124:166–74.
17. Davis R, Auerbach JD, Bae H, Errico TJ. Can low-grade spondylolisthesis be effectively treated by either coflex interlaminar stabilization or laminectomy and posterior spinal fusion? Two-year clinical and radiographic results from the randomized, prospective, multicenter US investigational device exemption trial: clinical article. *J Neurosurg Spine*. 2013;19:174–84.
18. Anderson PA, Tribus CB, Kitchel SH. Treatment of neurogenic claudication by interspinous decompression: application of the X STOP device in patients with lumbar degenerative spondylolisthesis. *J Neurosurg Spine*. 2006;4:463–71.
19. Bhav A. *Modern Techniques in Spine Surgery*. Bhav: Jaypee Brothers Medical Publishers. 2014:416–431.
20. Darwono AB. The new dynamic interlaminar device for the treatment of early and late lumbar degenerative problems. *Global Spine Journal*. 2014;4:132–8.
21. Caspar A, Jose MC, Giancarlo G, Riccardo M, Manuel L. The Intraspine® in the Treatment of L5-S1 Degenerative Disc Disease. Preliminary Report. *EC Orthopaedics*. 2015;2:146–52.
22. Kroeber M, Unglaub F, Guehring T, Nerlich A, Hadi T, Lotz J, Carstens C. Effects of controlled dynamic disc distraction on degenerated intervertebral discs: an in vivo study on the rabbit lumbar spine model. *Spine (Phila Pa 1976)*. 2005;30:181–7.
23. Choi J, Lee S, Hwangbo G. Influences of spinal decompression therapy and general traction therapy on the pain, disability, and straight leg raising of patients with intervertebral disc herniation. *J Phys Ther Sci*. 2015;27:481–3.
24. Wei H, Tang H, Zhang T, Chen H, Dong C. Preliminary efficacy of inter-spinal distraction fusion which is a new technique for lumbar disc herniation. *Int Orthop*. 2019;43:899–907.
25. Carragee EJ, Spinnickie AO, Alamin TF, Paragioudakis S. A prospective controlled study of limited versus subtotal posterior discectomy: short-term outcomes in patients with herniated lumbar intervertebral discs and large posterior anular defect. *Spine (Phila Pa 1976)*. 2006;31:653–7.

26. Choi KC, Kim JS, Park CK. Percutaneous Endoscopic Lumbar Discectomy as an Alternative to Open Lumbar Microdiscectomy for Large Lumbar Disc Herniation. *Pain Physician*. 2016;19:E291–300.
27. Steib K, Proescholdt M, Brawanski A, Lange M, Schlaier J, Schebesch KM. Predictors of facet joint syndrome after lumbar disc surgery. *J Clin Neurosci*. 2012;19:418–22.
28. Bono CM, Vaccaro AR. Interspinous process devices in the lumbar spine. *J Spinal Disord Tech*. 2007;20:255–61.
29. Xu C, Mao F, Wang X, Lin Y, Xu H. Application of the Coflex Interlaminar Stabilization in Patients With L5/S1 Degenerative Diseases: Minimum 4-Year Follow-up. *Am J Ther*. 2016;23:e1813–8.
30. Bowers C, Amini A, Dailey AT, Schmidt MH. Dynamic interspinous process stabilization: review of complications associated with the X-Stop device. *Neurosurg Focus*. 2010;28:E8.
31. Xu C, Ni WF, Tian NF, Hu XQ, Li F, Xu HZ. Complications in degenerative lumbar disease treated with a dynamic interspinous spacer (Coflex). *Int Orthop*. 2013;37:2199–204.
32. Guyer R, Musacchio M, Cammisa FP Jr, Lorio MP. ISASS Recommendations/Coverage Criteria for Decompression with Interlaminar Stabilization - Coverage Indications, Limitations, and/or Medical Necessity. *Int J Spine Surg*. 2016;10:41.
33. Guizzardi G. Looking at the Future of Motion Preservation Surgery in the Lumbar Spine with the Experience of the Past. *Global Spine Journal*. 2017;6:s-0036-1582979-s-1580036-1582979.
34. Bae J, Lee SM, Lee SH, Shin SH, Kim HJ, Kim KH. The Likelihood of Reaching Substantial Clinical Benefit After an Interlaminar Dynamic Spacer for Chronic Low Back Pain: A Clinical and Radiologic Analysis of a Prospective Cohort. *World Neurosurg*. 2017;101:589–98.
35. Mostofi K, Moghadam BG, Peyravi M. Interlaminar lumbar device implantation in treatment of Baastrup disease (kissing spine). *J Craniovertebr Junction Spine*. 2018;9:83–6.
36. Carrabs G, Sessa G, Oliva G, Magliulo M, Pipola AM, Silvestro A, Sica G. Intraspine Interlaminar Device: Clinical, Radiological, and Safety Results of a Mini Case Series (10 Cases). *Global Spine Journal*. 2015;5:s-0035-1554605-s-1550035-1554605.
37. Sobottke R, Schluter-Brust K, Kaulhausen T, Rollinghoff M, Joswig B, Stutzer H, Eysel P, Simons P, Kuchta J. Interspinous implants (X Stop, Wallis, Diam) for the treatment of LSS: is there a correlation between radiological parameters and clinical outcome? *Eur Spine J*. 2009;18:1494–503.
38. Guehring T, Unglaub F, Lorenz H, Omlor G, Wilke HJ, Kroeber MW. Intradiscal pressure measurements in normal discs, compressed discs and compressed discs treated with axial posterior disc distraction: an experimental study on the rabbit lumbar spine model. *Eur Spine J*. 2006;15:597–604.

Figures

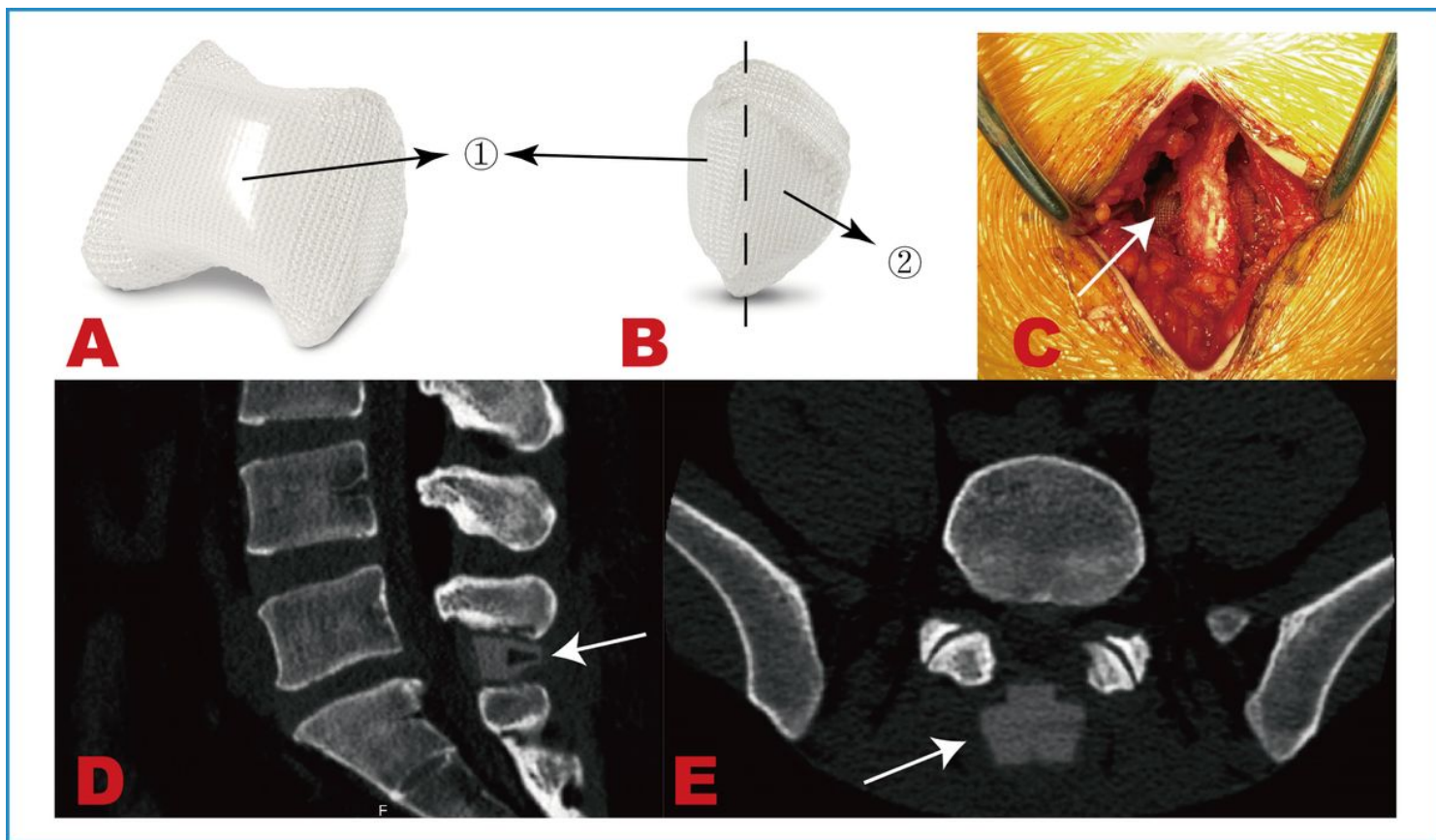


Figure 1

(A) Dorsal surface of IntraSpine interlaminar device. (B) Lateral view of IntraSpine interlaminar device. (C) Intraoperative image. (D) Sagittal CT in the L5/S1 level. (E) Axial CT in L5/S1 level revealed the anterior part of IntraSpine interlaminar device was attached to the ligamentum flavum. The arrow represented the position of the IntraSpine interlaminar device. (●1) Anterior part of IntraSpine interlaminar device, which is closer to the ligamentum flavum and mainly applies the effect of enlarging laminar space. (●2) Pnterior part of IntraSpine interlaminar device, mainly apply the effect of dynamic stability, which is located in interspinous position.

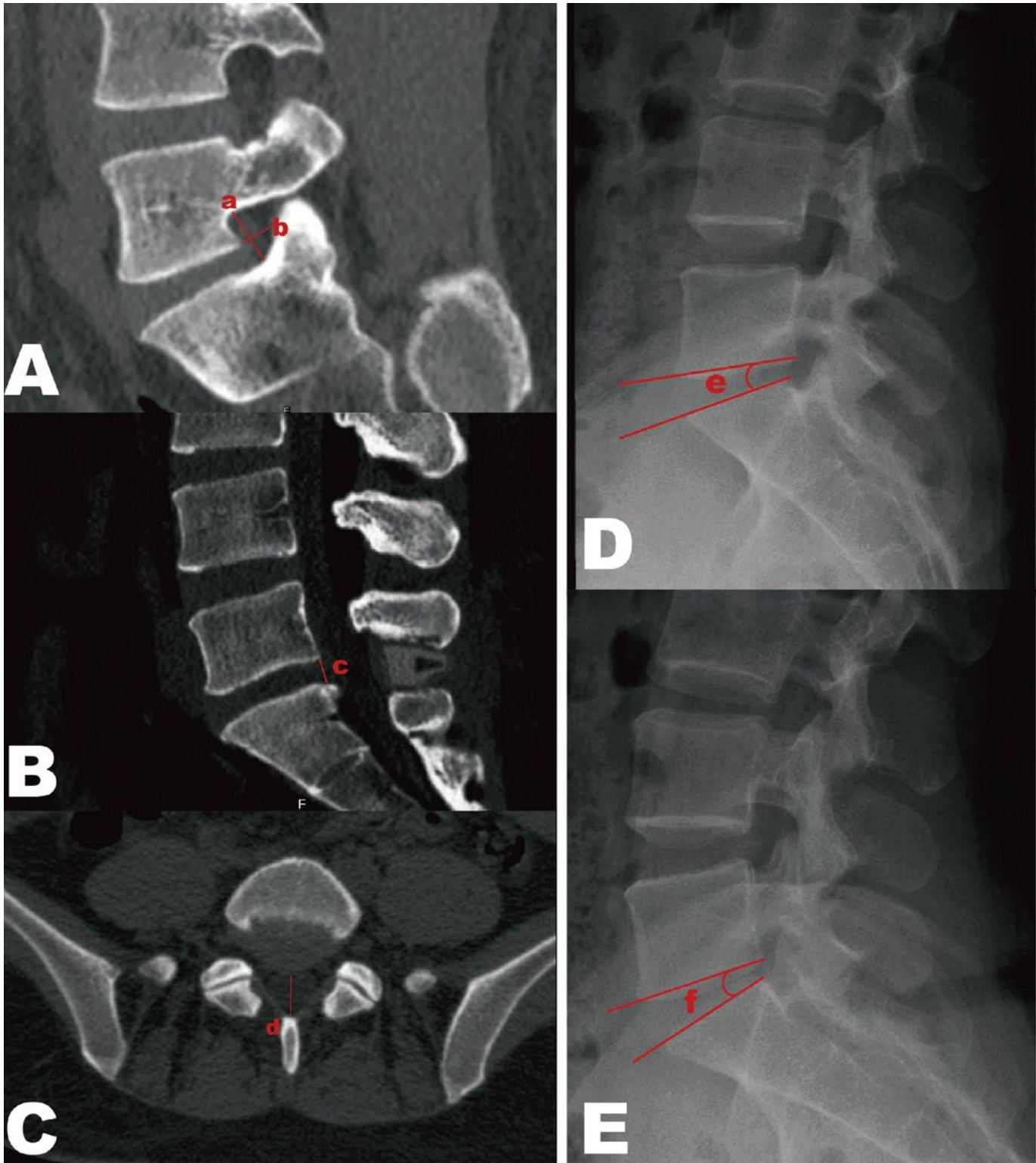


Figure 2

Measurement of imaging data. (A) Measurement of foramina height (a) and foramina width (b) in axial CT. (a) foramina height: the maximum distance between the inferior pedicle of the upper vertebra and the superior pedicle of the lower vertebra. (b) foramina width: the intersected level of extension of the inferior endplate of the upper vertebra with the foramina. (B) Measurement of posterior disc height (c) in axial CT: distance from the posterior edge of the inferior endplate of the upper vertebra and superior edge of the

lower vertebra. (C) Measurement of the sagittal diameter of the lumbar spinal canal (d): distance from the midpoint of the posterior edge of the vertebral body to the cortical midpoint of the inner margin of the vertebral plate. (D-E) Measurement of ROM of L5/S1 level by the lumbar flexion (D) and extension (E) of the X-ray film. (e): the intervertebral angle between the inferior endplate of the upper vertebra and superior endplate of the lower vertebra in lumbar flexion of the X-ray film. (f) the intervertebral angle between the inferior endplate of the upper vertebra and superior endplate of the lower vertebra in lumbar extension of the X-ray film. ROM= (f) – (e).

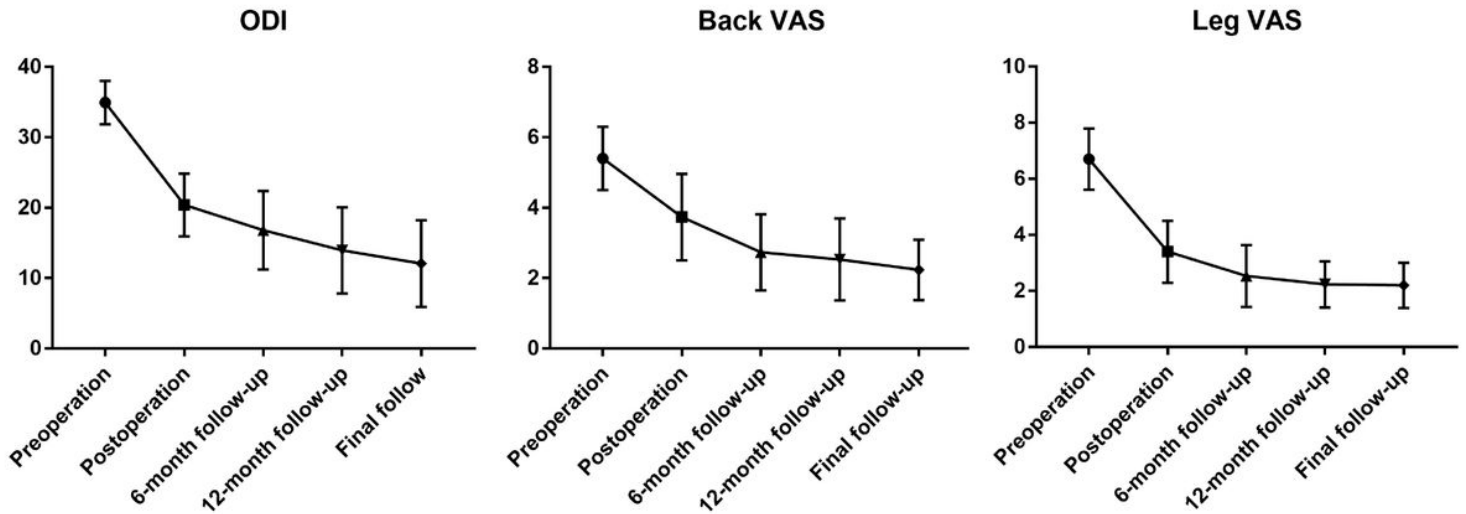


Figure 3

Line art of clinical data. Both VAS scores of low back and leg pains and ODI improved significantly from preoperative to postoperative ($P < 0.05$). The above indices at the 6-month follow-up, 12-month follow-up, and final follow-up were significantly different from those before surgery ($P < 0.05$).

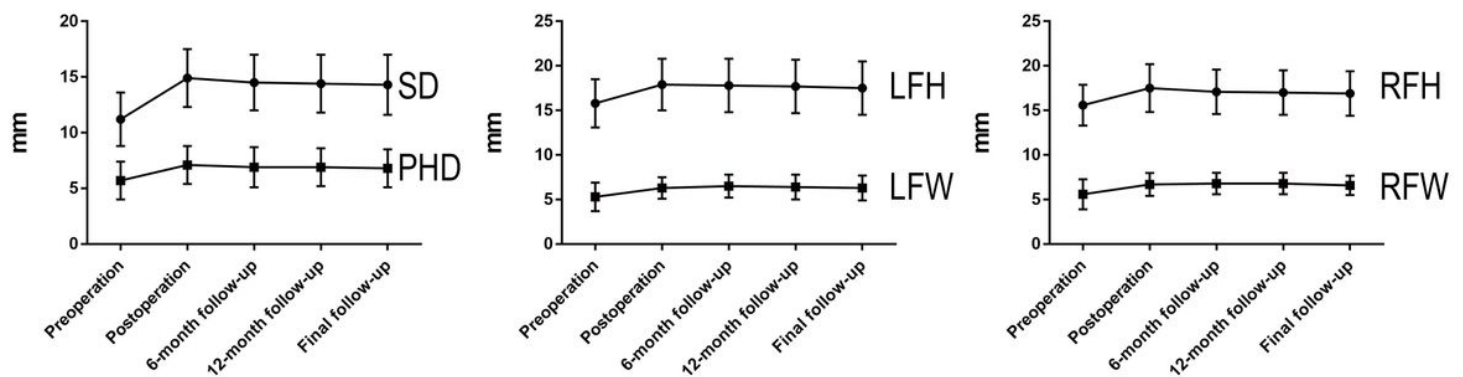


Figure 4

Line art of imaging data. Imaging data, including SD, PHD, LFH, RFH, LFW, and RFW, all improved significantly from preoperative to postoperative ($P < 0.05$).